

Healthcare CCI-RCES

CCI Registered Cardiac Electrophysiology Specialist
(RCES)

For More Information – Visit link below:

<https://www.examsempire.com/>

Product Version

1. Up to Date products, reliable and verified.
2. Questions and Answers in PDF Format.



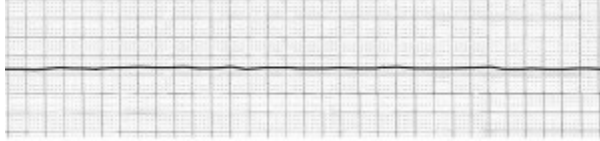
<https://examsempire.com/>

Visit us at: <https://www.examsempire.com/cci-rces>

Latest Version: 6.1

Question: 1

The cardiac rhythm strip above would be considered an example of _____?



- A. Ventricular tachycardia
- B. Atrial fibrillation
- C. Complete heart block
- D. Asystole

Answer: D

Explanation:

The cardiac rhythm strip above would be considered an example of asystole. Asystole, often referred to as "flatline," is a state where there is no cardiac electrical activity visible on the electrocardiogram (ECG). This absence of activity indicates that there is no cardiac output or effective heartbeat, and it is a type of cardiac arrest.

In the context of asystole, the heart's electrical system, which coordinates the contractions necessary to pump blood throughout the body, has ceased to function. The ECG strip would typically show a flat or almost flat line without any noticeable movement, reflecting the lack of electrical impulses within the heart.

Asystole is a critical condition requiring immediate medical intervention. Emergency treatment often involves cardiopulmonary resuscitation (CPR) and the administration of medications like epinephrine to stimulate the heart. However, the prognosis in asystole cases is generally poor unless the underlying cause can be quickly identified and treated.

It is essential to differentiate asystole from other cardiac rhythms, such as ventricular fibrillation or complete heart block, where some electrical activity is still present, and different treatment approaches are necessary. Recognizing asystole accurately on a rhythm strip is crucial for providing appropriate emergency care.

Question: 2

A primary manifestation of SA nodal dysfunction is which of the following?

- A. Sick sinus syndrome
- B. Tachycardia
- C. His-purkinje block
- D. Disordered automaticity

Answer: D

Explanation:

The correct answer to the question regarding a primary manifestation of SA nodal dysfunction is "disordered automaticity." The SA node, or sinoatrial node, is commonly referred to as the natural pacemaker of the heart. It generates electrical impulses that initiate each heartbeat, controlling the heart rate. This process is known as automaticity.

In the context of SA nodal dysfunction, disordered automaticity specifically refers to a condition where the inherent rhythm-generating capability of the SA node is impaired. Typically, this results in an abnormal reduction in the slope of phase 4 of the cardiac action potential. Phase 4 is crucial as it represents the spontaneous depolarization phase that leads to the generation of an action potential, which in turn initiates a heartbeat.

As a result of this reduced slope in phase 4 depolarization, the rate at which the SA node fires can decrease significantly, often leading to bradycardia, which is an abnormally slow heart rate. Patients with this condition may experience symptoms such as fatigue, dizziness, fainting spells, or even heart failure in severe cases.

To diagnose SA nodal dysfunction, electrophysiology studies are conducted in a clinical setting. One important diagnostic test used is the "sinus node recovery time" (SNRT). This test measures the time it takes for the sinus rhythm to resume after artificially pacing the heart at a set rate for a certain duration. An abnormally prolonged sinus node recovery time is indicative of SA nodal dysfunction, confirming issues with automaticity.

Overall, understanding and diagnosing disordered automaticity in the context of SA nodal dysfunction is crucial for managing and treating conditions related to abnormal heart rhythms effectively. Treatment may involve lifestyle changes, medication, or even pacemaker implantation, depending on the severity of the condition.

Question: 3

A scan that creates video images of the ventricles using radioactive materials given intravenously to display if they are pumping blood properly is known as all of the following except?

- A. A multigated acquisition scan
- B. Nuclear heart scan
- C. Echocardiogram
- D. Radionuclide ventriculography

Answer: C

Explanation:

The question asks to identify which of the listed options is not a type of scan that uses radioactive materials to create video images of the ventricles for assessing their blood-pumping efficiency. The options provided are: 1. Multigated acquisition scan 2. Nuclear heart scan 3. Echocardiogram 4. Radionuclide ventriculography

To answer this question, we first need to understand what each of these terms means and how they relate to imaging techniques that involve radioactive materials.

The **Multigated Acquisition Scan**, also known as MUGA scan, is a nuclear medicine procedure that evaluates the function of the heart's ventricles by using a radioactive tracer. The tracer emits gamma rays which are detected by a gamma camera to produce video images of the beating heart, and particularly, how well the ventricles are pumping blood.

The **Nuclear Heart Scan** encompasses various types of cardiac nuclear medicine imaging, including the MUGA scan. It generally involves the use of radioactive substances to assess the health and function of the heart, including ventricular function.

The **Radionuclide Ventriculography**, sometimes known as a radionuclide angiogram or gated blood pool scan, is another term for a nuclear imaging procedure that evaluates the function of the heart's ventricles. Similar to the MUGA scan, it uses a radioactive tracer to visualize the heart chambers and measure how effectively they pump blood.

On the other hand, an **Echocardiogram** is a different type of heart imaging technique that does not involve radioactive materials. Instead, it uses ultrasound waves to create images of the heart. This modality allows physicians to see the heart beating and pumping blood, providing valuable information about the size, structure, and movement of the heart's chambers and valves, as well as the heart's overall function.

Given the descriptions above, it is clear that the echocardiogram is the correct answer to the question as it is the only option listed that does not use radioactive materials to generate video images of the ventricles. The other options (Multigated acquisition scan, Nuclear heart scan, and Radionuclide ventriculography) all involve the use of radioactive tracers to assess ventricular function.

Question: 4

The anesthesia provider monitors the patient during electrophysiology procedures by assessing and monitoring all of the following except?

- A. Anesthesia level
- B. Vital signs
- C. Hemoglobin
- D. Cardiopulmonary function

Answer: C

Explanation:

During electrophysiology procedures, the anesthesia provider plays a critical role in ensuring the safety and comfort of the patient. This is achieved by monitoring various physiological parameters that reflect the patient's overall status under anesthesia. The parameters typically monitored include the level of anesthesia, cardiopulmonary function, vital signs, and intake and output. Each of these monitored factors plays a vital role in maintaining the patient's stability throughout the procedure.

The level of anesthesia is monitored to ensure that the patient remains unconscious and does not experience pain during the procedure. This involves the administration of anesthetic agents and continuous assessment to maintain the appropriate depth of anesthesia, tailored to the patient's needs and the specific requirements of the procedure.

Cardiopulmonary function is another critical aspect monitored by the anesthesia provider. This includes observing the heart rate, heart rhythm, blood pressure, and respiratory rate. Monitoring these parameters helps in detecting any cardiopulmonary instability that may arise during the procedure, such as arrhythmias, which are particularly relevant in electrophysiology studies.

Vital signs are a basic yet crucial set of measurements that provide immediate information about the patient's health during the procedure. These typically include measurements of blood pressure, heart rate, respiratory rate, and temperature. These signs help in identifying any acute changes that might necessitate immediate intervention to prevent complications.

Intake and output monitoring is crucial, especially in longer procedures, to balance fluids and ensure that the patient does not experience dehydration or fluid overload. This includes tracking all fluids administered (intake) and all bodily fluids lost or excreted (output).

However, contrary to what might seem intuitive, monitoring hemoglobin levels is not typically a primary focus during most electrophysiology procedures unless specific circumstances or the type of procedure dictates. Hemoglobin level monitoring is generally more critical in surgeries where significant blood loss is anticipated. In electrophysiology, the focus is primarily on electrical activities of the heart rather than on factors like hemoglobin levels, unless there is a preexisting concern that requires such monitoring.

In summary, during electrophysiology procedures, while the anesthesia provider does monitor an array of physiological parameters to ensure patient safety, hemoglobin levels are not typically among the primary factors monitored unless specific clinical indications exist. Instead, the focus is primarily on maintaining adequate anesthesia, ensuring stable cardiopulmonary function, monitoring vital signs, and managing fluid intake and output.

Question: 5

Of the following, which would not be considered a basic probe movement?

- A. Angling
- B. Sliding
- C. Rotating
- D. Covering

Answer: D

Explanation:

In the context of probe movements, particularly in fields like engineering, electronics, or medical diagnostics, understanding the fundamental techniques is crucial for effective manipulation and assessment. The basic movements typically include angling, sliding, rotating, and rocking. Each of these movements allows the user to control the probe in a way that optimizes the interaction with the object or surface being examined or worked upon.

****Angling**** involves tilting or adjusting the angle of the probe relative to the object. This is essential for getting a better view or interaction point, especially when surfaces are not uniform or when specific angles are required to properly assess the condition or structure beneath the surface.

****Sliding**** refers to moving the probe along the surface in a smooth motion. This movement is crucial for scans or when a continuous contact with the surface is required. It helps in gathering consistent data across a larger area without losing contact or altering the angle significantly during the movement.

****Rotating**** is turning the probe around its own axis. This movement allows the probe to explore different orientations without changing its position on the surface. This is particularly useful for circular or spherical objects where the probe needs to assess all sides or for intricate work where small rotations can lead to significant differences in diagnostics or work outcome.

****Rocking**** involves a pivoting motion, where the probe rocks back and forth over a point or area. This can help in determining the texture, resilience, or other physical characteristics of the surface. Rocking

can also be used to ensure better contact with uneven surfaces, allowing for more accurate readings or work.

On the other hand, **covering** is not considered a basic probe movement. Covering could imply either shielding the probe or the object or perhaps a technique related to ensuring the probe or the object is covered or coated during the procedure. This does not involve direct manipulation of the probe's position or orientation in relation to the object's surface, which is a defining characteristic of the basic probe movements. Therefore, covering is not classified alongside angling, sliding, rotating, or rocking in the context of fundamental probe movements.

Question: 6

The parts of a needle would be considered which of the following?

- A. Shaft
- B. Hub
- C. Cylinder
- D. Both A and B

Answer: D

Explanation:

To address the question about the parts of a needle and the options provided, it is essential to understand the components that make up a typical needle, especially in medical contexts such as injection needles. Below is an expanded explanation of each part mentioned in the question:

Hub

The hub is the part of the needle that attaches to the syringe. It is usually made of plastic and is designed to securely fit into the syringe's tip. The hub serves as the connection point and provides stability when the needle is in use.

Shaft: The shaft is the long, slender part of the needle that extends from the hub. It is typically made of stainless steel and is designed to penetrate the skin or other materials. The shaft's length and diameter can vary depending on the intended use of the needle.

Bevel: The bevel is the slanted tip of the needle. This design is crucial as it allows for smoother and easier penetration into the skin or other materials, minimizing discomfort and injury. The angle of the bevel can affect the sharpness and ease of insertion.

Cylinder is mentioned in one of the response options, but it is not a standard part of a needle. It might be a confusion with the barrel of a syringe, which is the cylindrical part that holds the fluid to be injected or drawn.

The question and its options seem to be formatted in a confusing manner, but it appears to ask which components are parts of a needle. Given the explanation of each part: - **Hub** is a part of a needle. - **Shaft** is a part of a needle. - **Bevel** is a part of a needle. - **Cylinder** is not a part of a needle but possibly refers to a part of a syringe.

Consequently, the correct response to the question would be "Both A and B" if the choices "A" and "B" refer to the Hub, Shaft, and Bevel as parts of a needle. The question format could be clearer, but based on common understanding of needle anatomy, these three elements are integral parts of a needle.

Question: 7

Which of the following is responsible for transferring the electrical impulse from the AV node to the ventricles?

- A. Sinus node
- B. His bundle
- C. Purkinje fibers
- D. Fibrous skeleton of the heart

Answer: B

Explanation:

The correct answer to the question of which structure is responsible for transferring the electrical impulse from the atrioventricular (AV) node to the ventricles is the His bundle. The His bundle, also known as the bundle of His, plays a critical role in the cardiac conduction system, which ensures the proper coordination of the heartbeat.

The cardiac conduction system is a group of specialized cardiac muscle cells in the walls of the heart that send signals to the heart muscle causing it to contract. The major components of this system include the sinoatrial (SA) node, the AV node, the His bundle, the bundle branches, and the Purkinje fibers. Each component has a specific function in the sequence of the heartbeat.

The process begins at the SA node, often referred to as the natural pacemaker of the heart, located in the right atrium. It generates an electrical impulse that causes the atria to contract and push blood into the ventricles. This impulse then travels to the AV node, which is located at the junction between the atria and ventricles. The AV node acts as a gatekeeper; it slightly delays the impulse, providing sufficient time for the ventricles to fill with blood before they contract.

From the AV node, the impulse is transmitted to the His bundle. The His bundle is a collection of heart muscle cells specialized for electrical conduction. These cells are located at the top of the interventricular septum, the wall that divides the left and right ventricles. The His bundle transmits the electrical impulse from the AV node to the bundle branches—the right and left bundle branches that run along the sides of the interventricular septum.

The bundle branches then conduct the impulse to the Purkinje fibers, which distribute the impulse throughout the ventricles, causing them to contract uniformly. This contraction propels blood out of the heart to the lungs and the rest of the body.

Therefore, the His bundle is essential for the proper transmission of electrical impulses from the upper parts of the heart (atria) to the lower parts (ventricles). It ensures that the ventricles receive the signal to contract after the atria have emptied their blood into the ventricles, maintaining the efficiency and coordination of the heartbeat.

Question: 8

Of the following, which could potentially cause the development of PVC's (premature ventricular contractions)?

- A. Heart failure
- B. Nicotine
- C. Increased work load on the heart
- D. All of the above

Answer: D

Explanation:

Premature ventricular contractions (PVCs) are extra heartbeats that originate in one of the heart's two lower pumping chambers (ventricles). These extra beats disrupt the regular heart rhythm, sometimes causing a sensation of a skipped beat in the chest. While PVCs can appear in healthy individuals without significant consequences, they can also be an indicator of more serious heart conditions or be prompted by various external factors.

Among the potential causes of PVCs, heart failure is a critical condition where the heart's ability to pump blood effectively is compromised. This inefficiency can strain the heart, leading to various cardiac electrical instabilities including PVCs. Factors like increased workload on the heart, such as from hypertension or valve disorders, can also provoke PVCs by putting additional stress on the cardiac muscle.

External substances like nicotine and caffeine can trigger PVCs as well. Nicotine stimulates adrenaline production, which in turn can enhance cardiac activity and potentially lead to rhythm disturbances. Similarly, caffeine can increase heart rate and promote stronger heart contractions, conditions that may induce PVCs.

Cardiac ischemia, which refers to reduced blood flow to the heart muscle, and cardiac infarction, commonly known as a heart attack, both directly impact heart muscle function and can disturb the normal electrical pathways, leading to PVCs. Digitalis toxicity, another cause, arises from the medication digitalis used in treating heart conditions; it can lead to various arrhythmias, including PVCs, especially if the drug levels in the blood become too high.

Lastly, electrolyte imbalances involving key ions like potassium, magnesium, and calcium, which are crucial for proper electrical signaling in the heart, can also lead to PVCs. Imbalances might occur due to diet, kidney function, or other metabolic disturbances.

Given these potential triggers and underlying conditions, the answer "All of the above" is appropriate when considering what could potentially cause the development of PVCs. Each listed factor can independently or in combination with others influence the occurrence of these premature heartbeats. Understanding these causes is essential for managing or preventing PVCs, especially in individuals with underlying heart conditions or those exposed to the mentioned external factors.

Question: 9

The primary source of airborne bacteria in the electrophysiology lab is which of the following?

- A. The patient
- B. The equipment
- C. The air vents
- D. The personnel

Answer: D

Explanation:

The primary source of airborne bacteria in the electrophysiology lab is "The personnel."

In an electrophysiology lab, maintaining a sterile environment is crucial to prevent infections and ensure the safety of both patients and staff. Despite rigorous cleaning protocols and equipment sterilization, one significant source of airborne bacteria often overlooked is the personnel themselves.

Human beings naturally harbor bacteria on their skin, in their respiratory tracts, and in the gastrointestinal system. When lab personnel talk, cough, or sneeze, they can expel droplets that contain these bacteria into the air. Even smaller particles that are released during normal breathing or through the shedding of skin can contribute to the bacterial load in the environment.

In addition to respiratory and skin emissions, the clothing and equipment used by the personnel can also be sources of contamination. Bacteria can cling to fabrics and objects, which, when disturbed, release these microorganisms into the air. This is why hospitals and labs enforce strict guidelines regarding the use of protective clothing like gowns, gloves, masks, and sometimes even hairnets.

The risk of contamination increases with the number of people in the room and the duration of exposure. Therefore, it's recommended to limit personnel traffic in and out of sensitive areas such as the electrophysiology lab. Conversations should also be minimized in areas where sterile procedures are being conducted to reduce the risk of droplet-spread bacteria.

While the air handling systems (air vents) and other equipment can also contribute to airborne contamination, these are typically designed with filters and sterilization technologies to minimize risk. However, no matter how advanced, these systems cannot completely eliminate the risk posed by human activity.

Therefore, it is essential for personnel to adhere strictly to hygiene protocols, including hand washing, proper attire, and minimizing unnecessary movements and conversations in critical areas to help maintain the aseptic conditions required in an electrophysiology lab.

Question: 10

All but which of the following equipment might be needed when transporting a patient to the electrophysiology (EP) suite?

- A. Pulse oximetry
- B. Portable oxygen
- C. Cut-down tray
- D. Intubation equipment

Answer: C

Explanation:

To determine which equipment might not be needed when transporting a patient to the electrophysiology (EP) suite, it's important to understand the typical requirements and procedures involved in EP studies. Electrophysiology studies focus on diagnosing and treating heart rhythm disorders (arrhythmias). The procedures generally involve the use of catheters and specialized equipment to measure and map electrical signals within the heart. ****Pulse Oximetry****: This is a non-invasive method to monitor the oxygen saturation of a patient's blood. It is crucial for observing the patient's oxygen levels during transport, especially if they have cardiovascular issues, which are common among patients going to the EP suite. ****Portable Oxygen****: Given that patients with heart conditions may experience difficulty in breathing or decreased oxygen saturation, portable oxygen is essential during the transport to maintain adequate oxygenation. ****Intubation Equipment****: This equipment might be required for patients who are unable to maintain adequate airway control or proper gas

exchange. It's a precautionary measure during transport, particularly if the patient's respiratory status is compromised or expected to be unstable. **Cut-down Tray**: This equipment is typically used for emergency vascular access when peripheral access is not feasible. It includes tools needed for incising the skin and accessing a vein or artery directly. While it's crucial in emergency or specific surgical settings, it might not be immediately necessary for routine transport to an EP suite where the procedure primarily involves catheter use through peripheral veins or arteries. **Portable EKG Monitor**: Essential for monitoring the heart's electrical activity during transport. Given that the patient is heading for an EP study, continuous monitoring is crucial to detect any arrhythmic events en route. **Stethoscope**: Basic but vital, a stethoscope allows healthcare providers to auscultate the heart and lungs during transport. This is important for assessing the cardiopulmonary status of the patient. **Spirometer**: While useful for assessing lung function, it's not typically essential during the actual transport to an EP suite unless specific respiratory evaluations are necessary en route. From the items listed, the **Cut-down Tray** is the least likely to be required during routine transport to an EP suite. This is because EP studies generally focus on diagnosing and treating conditions related to the electrical functions of the heart, and vascular access can usually be achieved through less invasive means than those provided by a cut-down tray.

Thank You for Trying Our Product
Special 16 USD Discount Coupon: NSZUBG3X
Email: support@examsempire.com

**Check our Customer Testimonials and ratings
available on every product page.**

Visit our website.

<https://examsempire.com/>